



Midtown Sports Imaging

20 E 46th St Rm 202, New York, NY 10017

(Corner of East 46th Street and Madison Avenue)

Tel (212) 888-9599 Fax (212) 888-9699

Date: _____

Patient Name: _____

Referred by: _____ Telephone: _____

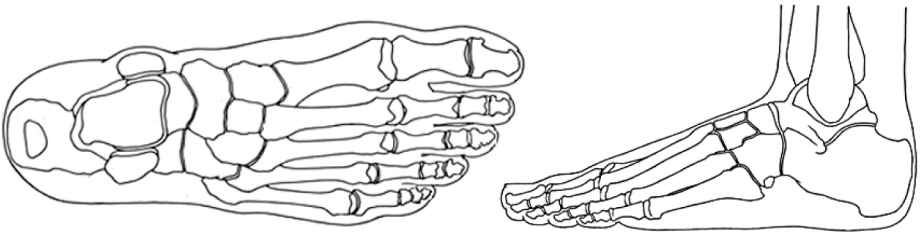
Diagnosis/Clinical History/Previous Surgery: _____

IMAGING OF THE FOOT / ANKLE

FOOT: LEFT RIGHT

ANKLE: LEFT RIGHT

Please mark X at the location of suspected pathology:



INDICATIONS

- Tarsal tunnel / sinus tarsi
- Mass (Morton's neuroma, ganglion, etc.)
- Plantar fasciitis or fibromatosis
- Tendinopathy or ligamentous pathology
- Fracture or contusion
- Infection: cellulitis vs. osteomyelitis
- Tarsal coalition
- Other _____

Rule out / notes: _____